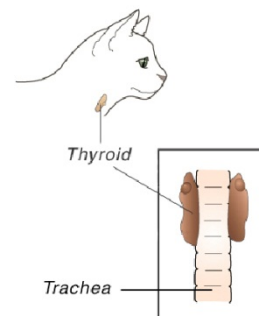


Hyperthyroidism in Cats

The thyroid glands are located in the neck and play a vital role in regulating the body's metabolic rate. *Hyperthyroidism* is a disorder characterized by the overproduction of thyroid hormone and a subsequent increase in the metabolic rate. This is a common disease of older cats. Although the thyroid gland enlarges in hyperthyroidism, it is usually a benign or non-malignant change. Less than 2% of hyperthyroid cases involve malignant thyroid gland tumors.

Many organs are affected by hyperthyroidism, including the heart. The heart is stimulated to pump faster and more forcefully; eventually, the heart enlarges to meet these increased demands for blood flow. The increased pumping pressure leads to a greater output of blood and subsequent high blood pressure. About 25% of cats with hyperthyroidism have high blood pressure.



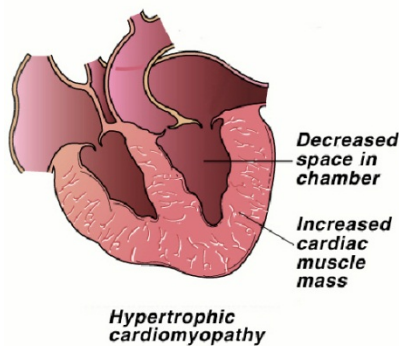
Are certain cats more likely to develop hyperthyroidism?

Older cats are at increased risk for developing hyperthyroidism. Environmental and dietary risk factors have been investigated. They may predispose some cats to hyperthyroidism, although the specific mechanisms are not known. No individual breed is known to be at increased risk, although the Siamese appears to have a somewhat increased incidence of hyperthyroidism compared to other breeds.

What are the clinical signs of hyperthyroidism?

"The typical cat with hyperthyroidism is middle aged or older."

The typical cat with hyperthyroidism is middle aged or older. The average age of affected cats is approximately twelve years. The most common clinical sign of hyperthyroidism is **weight loss** secondary to the increased rate of metabolism. The cat tries to compensate for this with an increased appetite. In fact, some of these cats have a ravenous appetite and will literally eat anything in sight! Despite the increased intake of food, most cats continue to lose weight. The weight loss may be so gradual that some owners will not realize it has occurred, or the weight loss may be quite rapid. Affected cats often have **increased water consumption and urination**. There may be periodic **vomiting or diarrhea**, and the **fur may appear unkempt**. In some cats, **anorexia** develops as the disease progresses.



Two secondary complications of hyperthyroidism can be significant. These include *hypertension* (high blood pressure) and heart disease called *thyrotoxic cardiomyopathy*. Hypertension develops due to the increased pumping pressure and elevated heart rate that occurs with thyrotoxic cardiomyopathy. In some cats, blood pressure can become so high that retinal hemorrhage or retinal detachment will occur and result in sudden blindness.

"Both the cardiomyopathy and the hypertension are potentially reversible..."

Heart problems develop because the heart must enlarge and thicken to meet the increased metabolic demands. In some cases, the cat will develop a heart murmur associated with the cardiomyopathy. Both the cardiomyopathy and the hypertension are potentially reversible with appropriate treatment of the disease. However, unless the retinal detachment is treated immediately, permanent blindness can result.

What causes hyperthyroidism?

Some of the risk factors for hyperthyroidism have been defined above. A specific cause for hyperthyroidism has not been identified. The possible role of dietary iodine continues to be investigated as a dietary influence on development of hyperthyroidism.

How is hyperthyroidism diagnosed?

"In most instances, diagnosis of this disease is relatively straightforward."

In most instances, diagnosis of this disease is relatively straightforward. The first step is to determine the blood level of one of the thyroid hormones, called *total thyroxine* (or TT_4). Usually, the TT_4 level is so high that there is no question as to the diagnosis. Occasionally, a cat that is suspected of having hyperthyroidism has a TT_4 level within the upper range of normal. When this occurs, a second test, usually either a Free T_4 by Equilibrium Dialysis (FT_4 by ED) or a T_3 Suppression Test is performed. If these tests are not diagnostic, a thyroid scan can be performed at a veterinary referral center or the TT_4 can be measured again in a few weeks.



How is hyperthyroidism treated?



Because less than 2% of cats with hyperthyroidism have cancerous growths of the thyroid gland, treatment is usually very successful.

Several tests are performed before choosing any form of treatment. These tests are needed to evaluate the overall health of the cat and predict the chances for complications with the chosen treatment protocol. Such tests include blood tests, urinalysis, chest x-rays, ECG, and blood pressure measurement. Cardiac ultrasound or echocardiography may be recommended based on your cat's condition, especially if there is any concern about cardiomyopathy.

"There are three choices for treatment; any one of them could be the best choice in certain situations."

There are three choices for treatment; any one of them could be the best choice in certain situations. Many factors must be considered when choosing the best therapy for an individual cat. The three treatment options for hyperthyroidism are:

1. **Radioactive iodine.** A very effective way to treat hyperthyroidism is with radioactive iodine therapy (I^{131}). An injection of radioactive iodine is given intravenously, and it destroys the abnormal thyroid tissue without endangering other organs. Treatment usually requires one or two weeks of hospitalization at a veterinary hospital licensed to administer radiation therapy.
2. **Surgery.** Surgical removal of the affected thyroid gland(s) is also very effective. Because hyperthyroid cats are usually over eight years of age, there is a degree of risk involved. However, if the cat is otherwise healthy and the initial diagnostic tests and treatment did not reveal any underlying conditions, the risk is minimal. If the disease involves both lobes of the thyroid gland, two surgeries may be required, depending on the surgeon's choice of procedures. In many cats, only one thyroid lobe is abnormal, so only one surgery is needed.

If surgery is the treatment method chosen, the anti-thyroid medication methimazole may be prescribed for several weeks prior to the operation. During that time, the ravenous appetite should subside, the cat will probably gain weight, and the blood pressure and heart rate should normalize. Anti-thyroid medication is given to determine if the cat has a secondary medical condition such as kidney or liver disease that has been masked by hyperthyroidism. If your cat successfully undergoes the initial treatment without complication, surgery will be performed.

Your cat may be hospitalized for one to two nights following surgery, and should begin to eat and behave normally after returning home. One to two weeks, after surgery, another TT_4 level is measured.

3. **Oral medication.** Administration of an oral drug, methimazole (Tapazole®), can control the effects of the overactive thyroid gland. Some cats may have reactions to the drug, but that number is small (less than 20%). However, the side effects may begin as late as six months after the beginning of treatment and can include vomiting, lethargy, anorexia, fever, liver damage, anemia and a decrease of white blood cells in the blood (*agranulocytosis*) may occur. In some cases, a decrease in blood platelets (*thrombocytopenia*) also may occur. Since platelets are important for the clotting of blood, thrombocytopenia may lead to problems with excessive bleeding. Because of the risk of these rare but serious side effects, your cat will need to be closely monitored by simple having blood tests performed every three to six months when using this drug.

Methimazole blocks the production of excess thyroid hormone rather than destroying the abnormal thyroid tissue. Therefore, the drug must be given for the remainder of the cat's life. This type of treatment is appropriate for the cat that is a poor surgical risk due to other health problems or is exceptionally old. As stated above, it may also be used for a few weeks to stabilize the cat that is at increased surgical risk because of cardiac complications.

Will my cat be cured with treatment?



Recurrence of the disease is a possibility in some cats. It is uncommon after radioactive iodine therapy. When surgery is done, recurrence is possible if any abnormal thyroid cells remain. If these residual cells grow, the disease will recur.

"Recurrence of the disease is a possibility in some cats."

However, this occurs less than 5% of the time, usually two to four years after surgery. Another possibility for disease recurrence is that one lobe of the thyroid gland was normal at the time of surgery so it was not removed. Then, months or years later, it becomes abnormal.

What is the prognosis for hyperthyroidism?

Many owners of cats with hyperthyroidism are hesitant to have radiation therapy or surgery because of their cat's advanced age. It is important to remember that age is not a disease.

"The outcomes following either surgery or radiation therapy are usually excellent..."

The outcomes following either surgery or radiation therapy are usually excellent, and most cats have a very good chance of returning to a normal state of health. Cats managed medically also often do well as long as the medication is administered routinely and follow-up blood and diagnostic test schedules are performed.

Can hyperthyroidism be prevented?

There are no currently-known preventive measures for hyperthyroidism, but early diagnosis decreases the secondary problems and improves the prognosis. All middle-aged and senior cats should receive a complete physical examination by a veterinarian every six to twelve months. Special attention should be given to the thyroid glands, looking for evidence of enlargement and the typical clinical signs of hyperthyroidism. Annual blood and urine tests are important in all cats over age six to detect hyperthyroidism before potentially irreversible damage occurs.

Ernest Ward, DVM

© Copyright 2009 Lifelearn Inc. Used and/or modified with permission under license.